

Case Panel Presentation

Franz Landauer MD (A)

Patrick Knott MD (US)

Fabio Zaina MD (I)

Manuel D. Rigo MD (S)

Case 1

Girl

12 years and 9 months old

Family history negative

T10-L2 left convex curve 16° Cobb

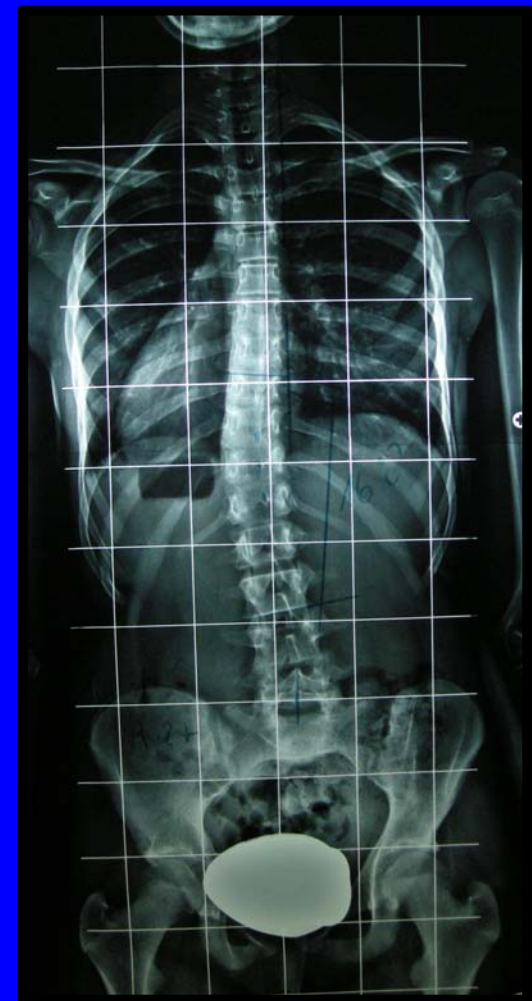Rotation: Degree I (Nash-Moe) ± 5

Risser 2++

Pre-menarche

Recommendation was: to do nothing

'it was done'



Case 1

16 y and 7 months

2 years post-men

ATI 9°

164 cm

52.5 Kg

T9-L2 35° Cobb Risser 4 ++

Rotation: Degree II (T12)

SRS 22

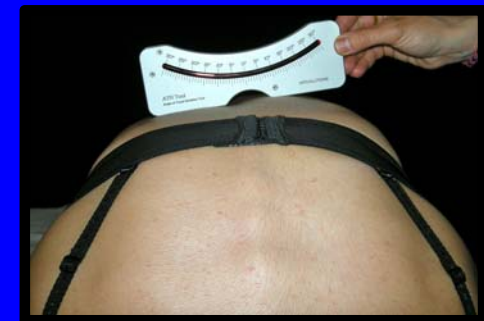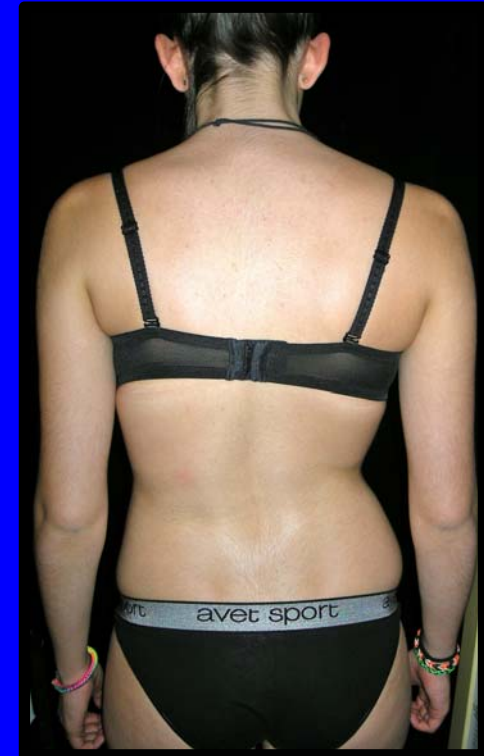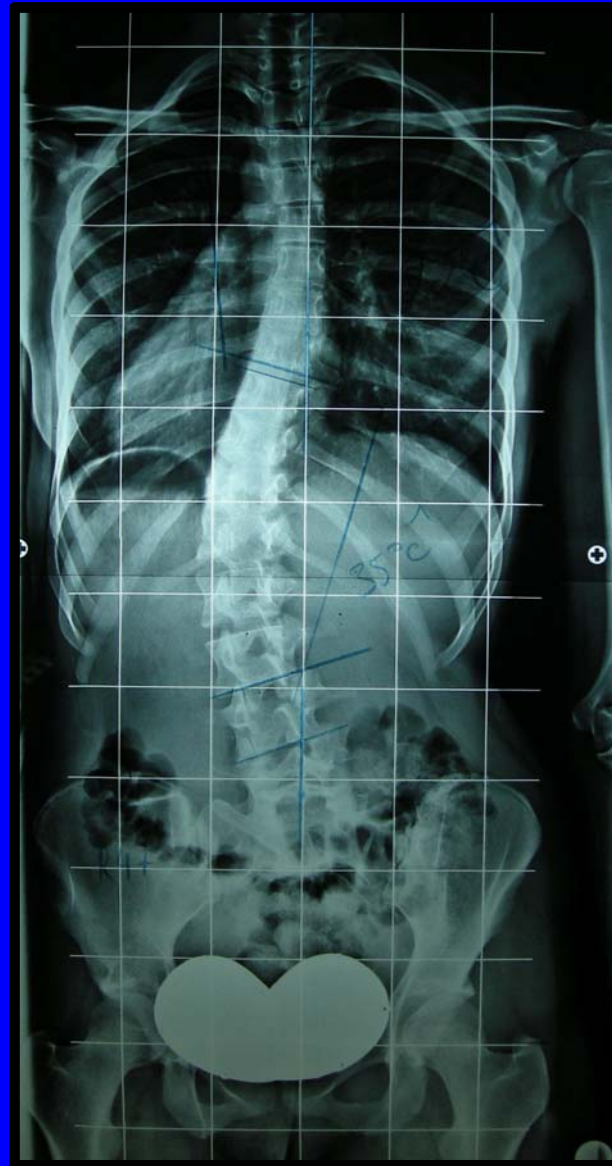P 4.2

MH 4.2

SI 2.8

F 4.6

TAPS 10 (3-15)



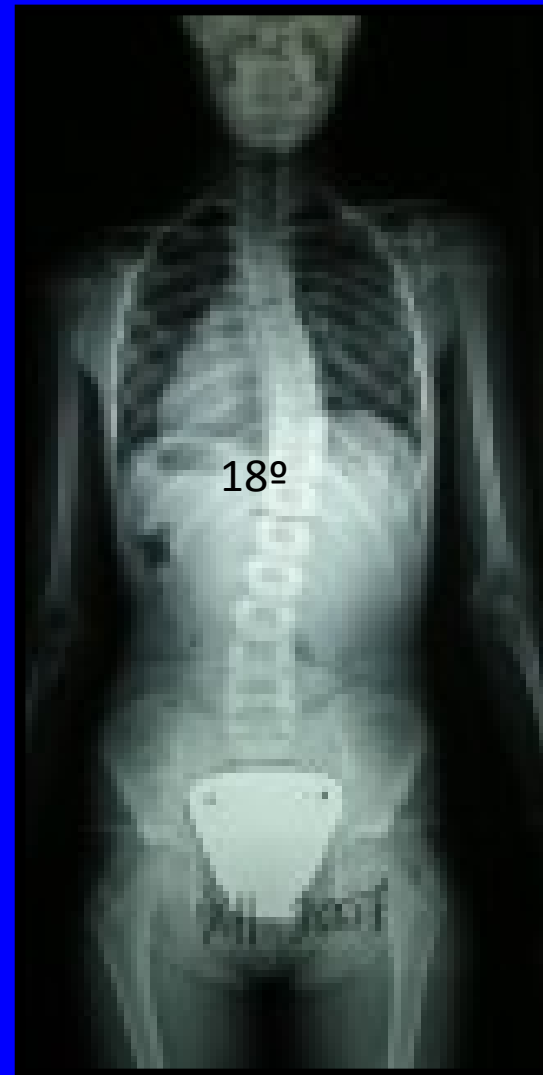
Case 2

Girl 7 years of age

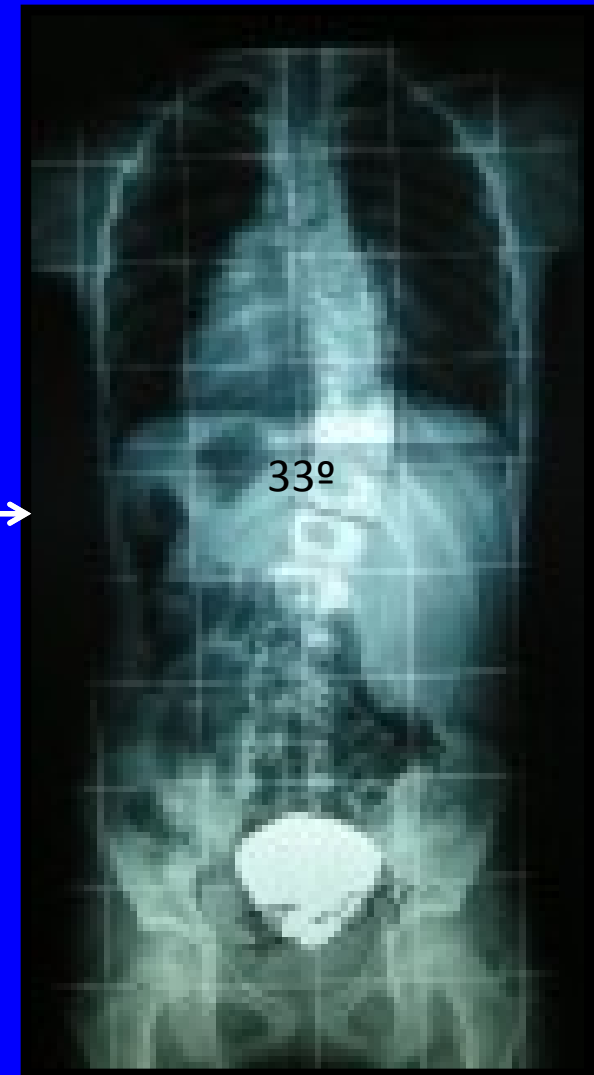FH –

No signs ≠ IS

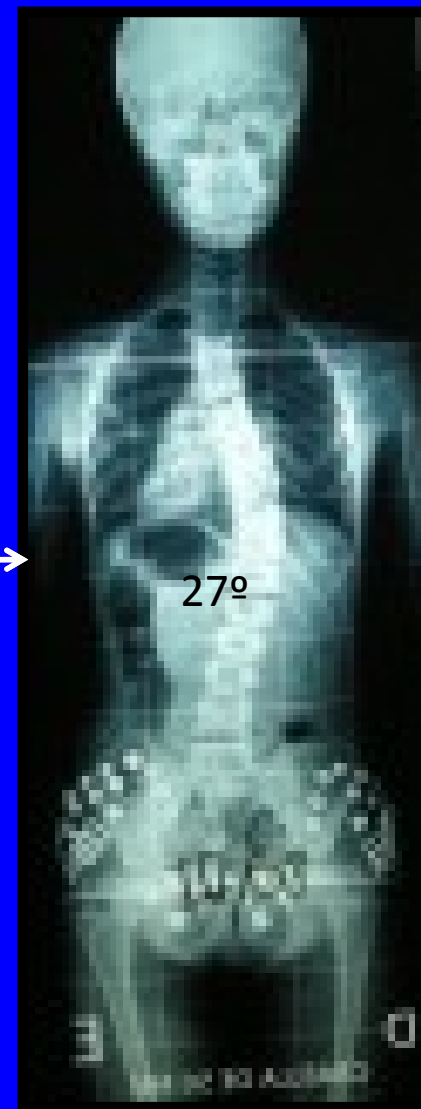
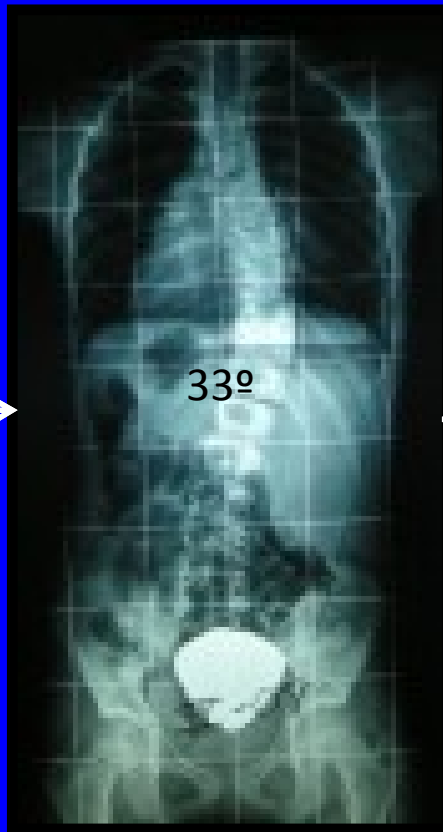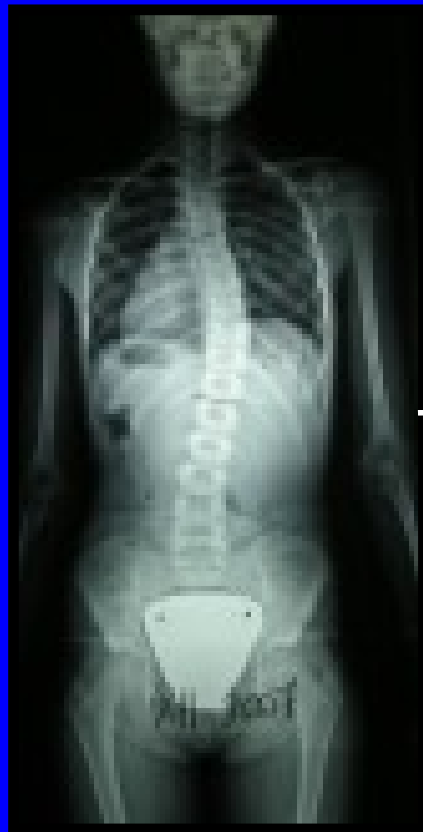No other information



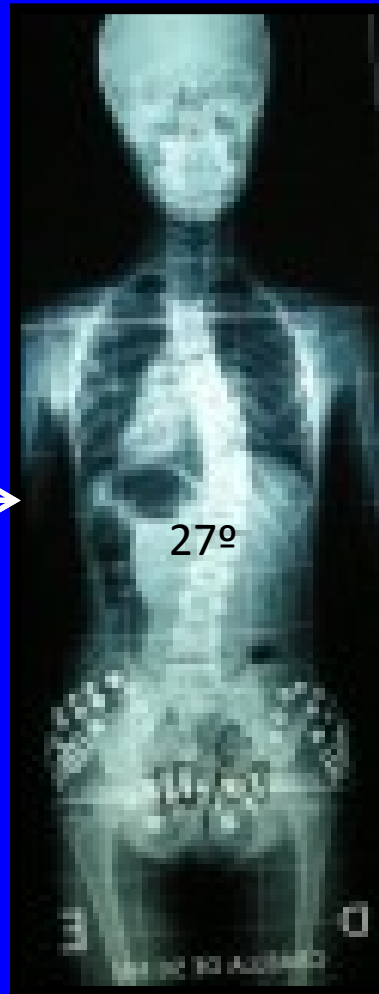
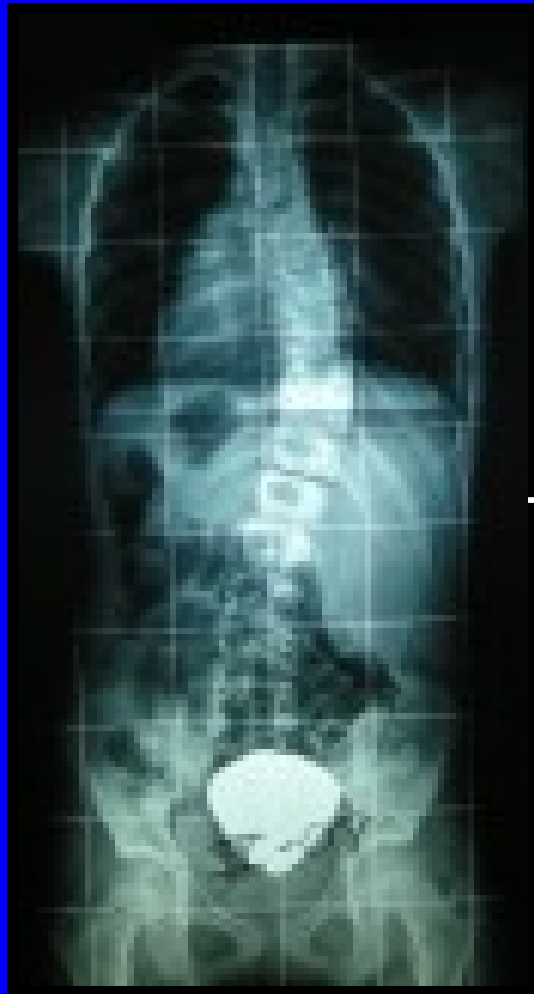6 m



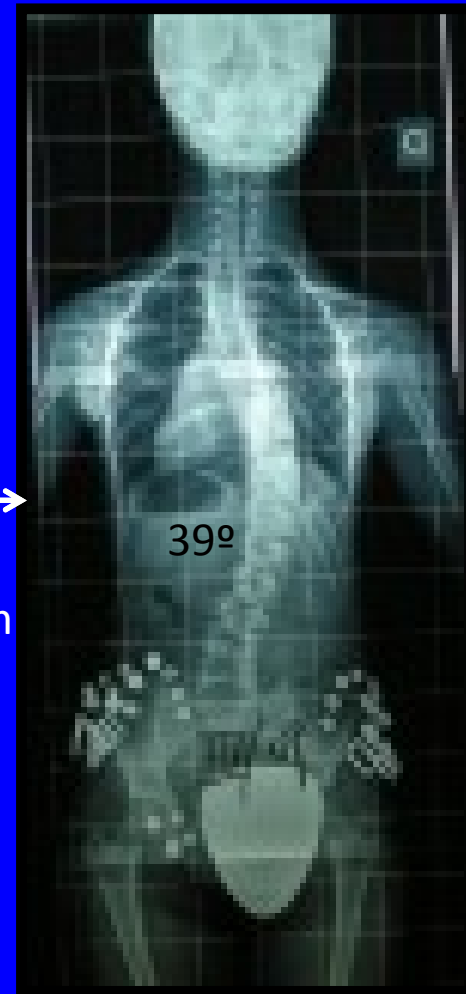
Recommendation ?



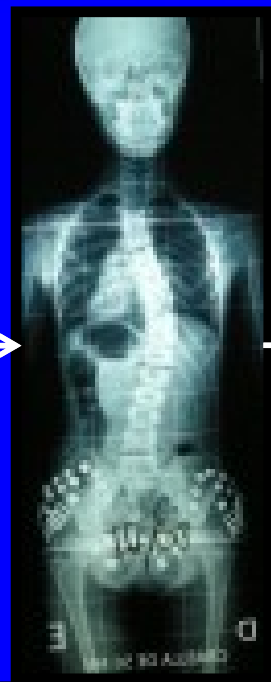
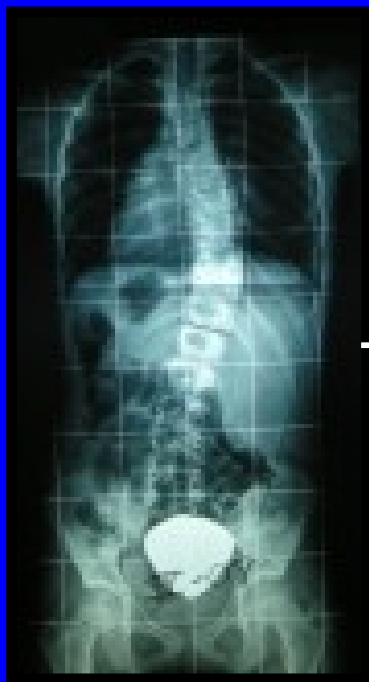..she was recommended to wear a SpineCor



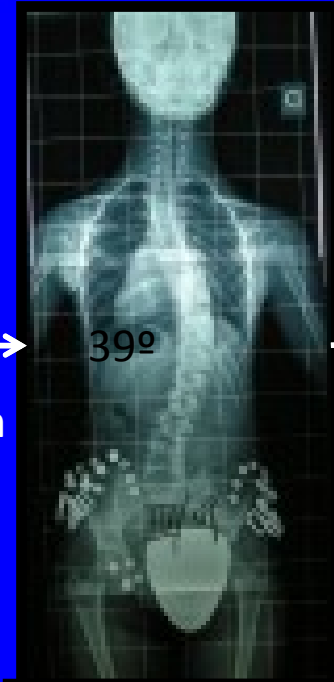
12 m



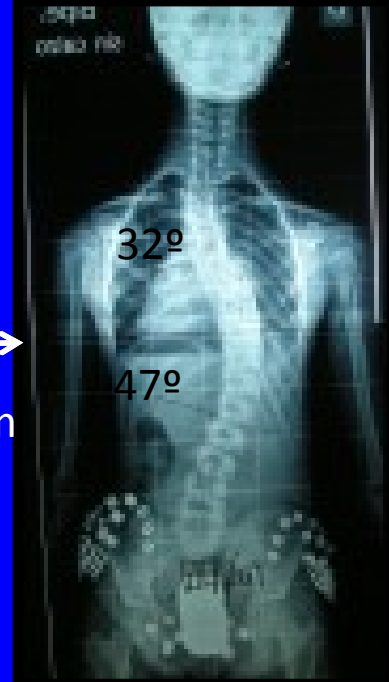
8 y



12 m

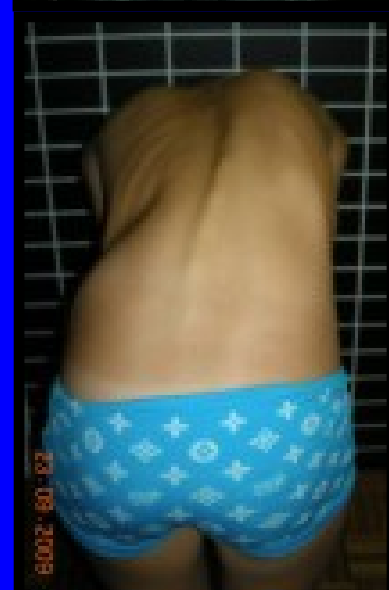


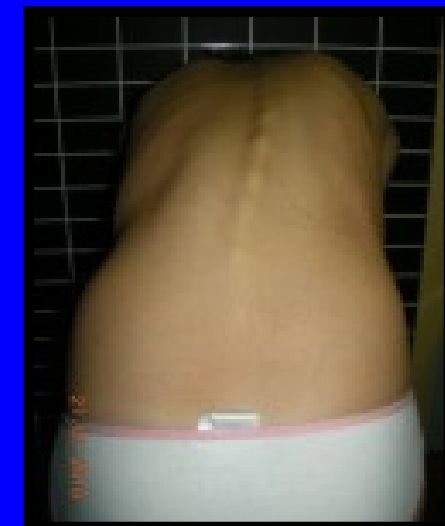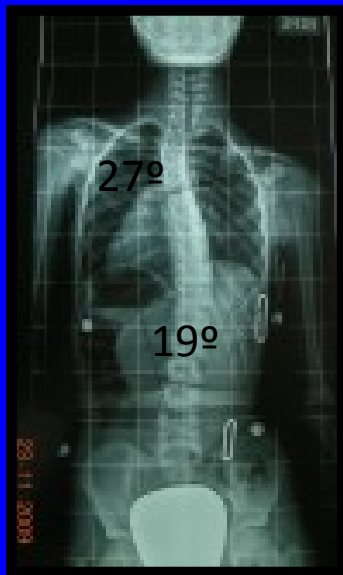
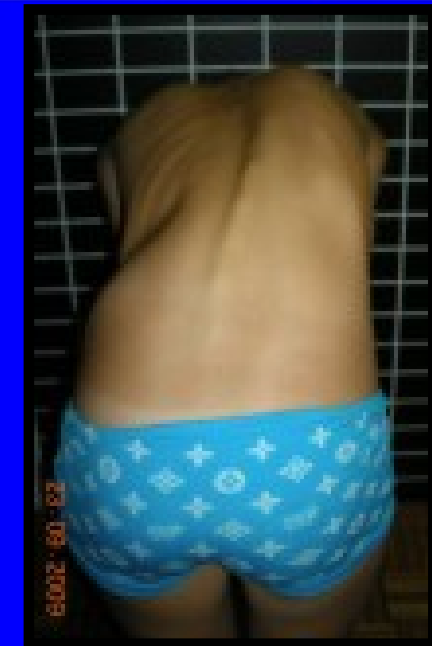


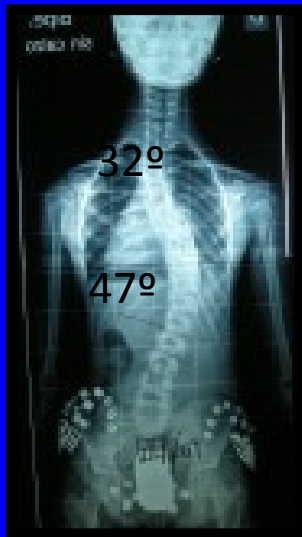
12 m



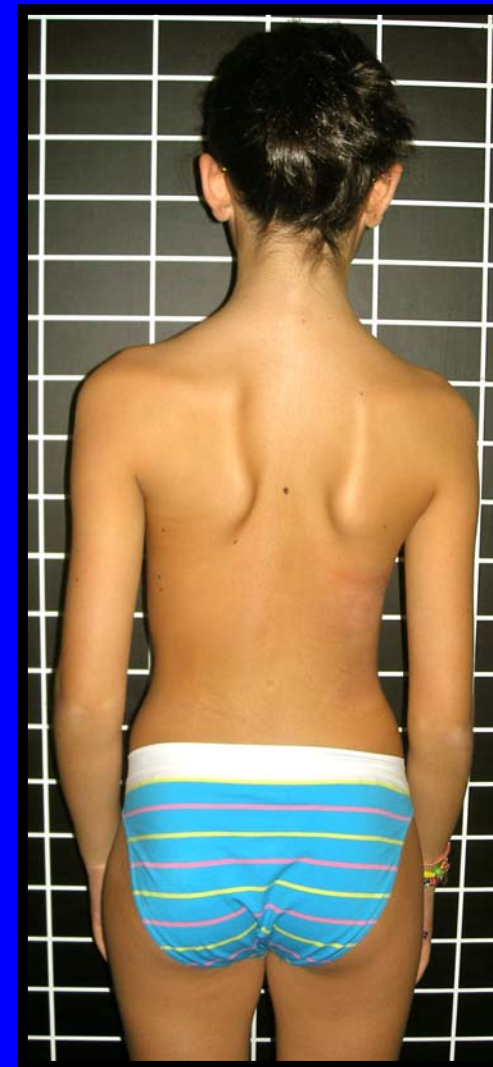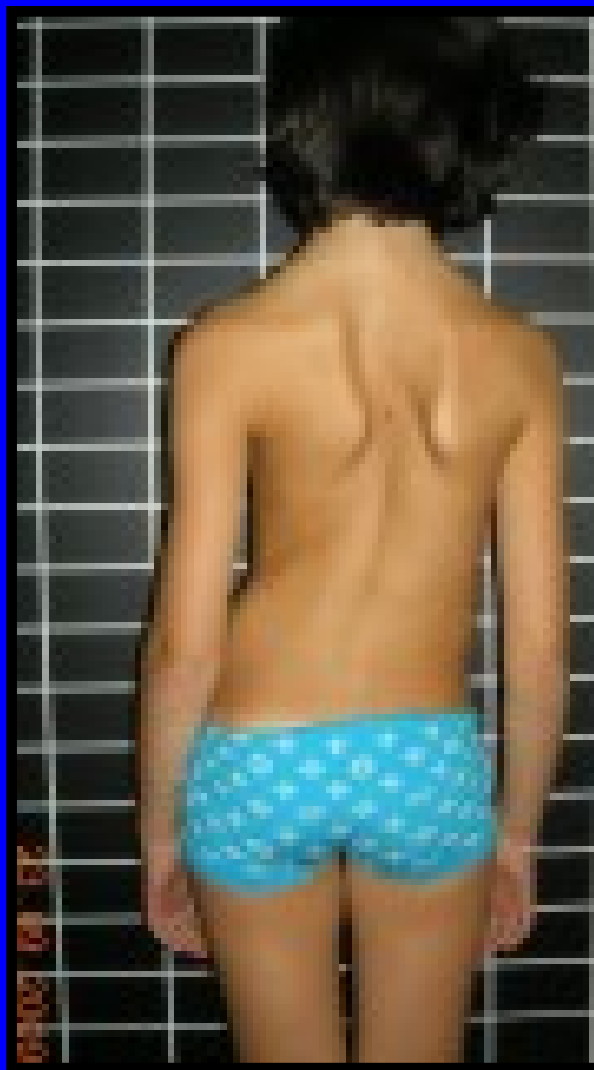


9 years

TREATMENT
FAILURE



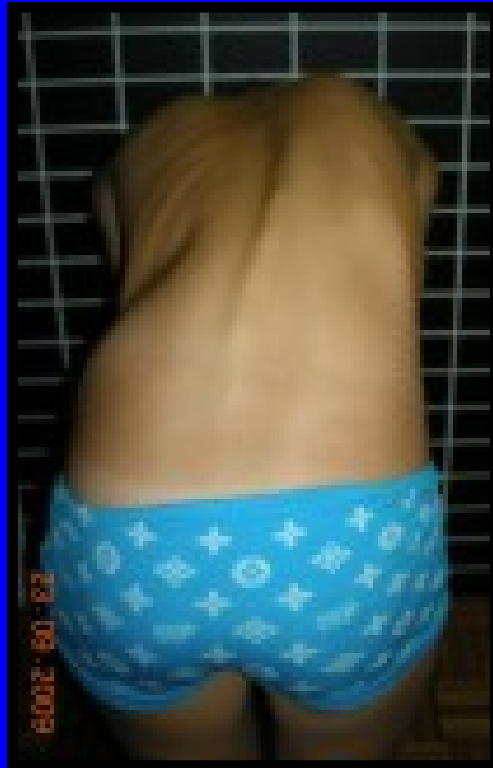

At six months of treatment

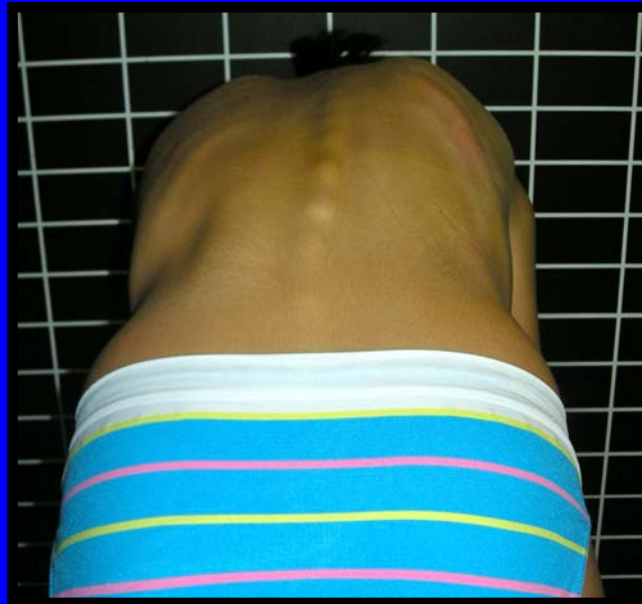

At one year of treatment

Sept. 09

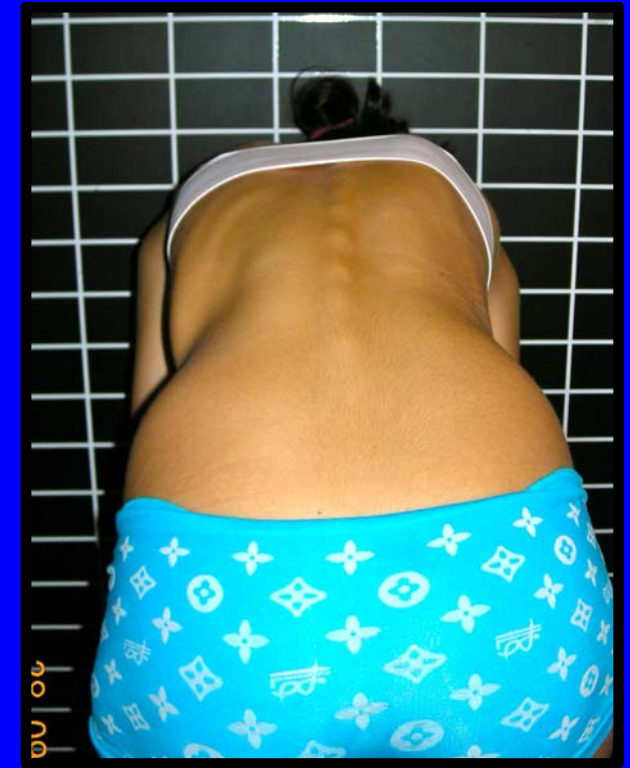

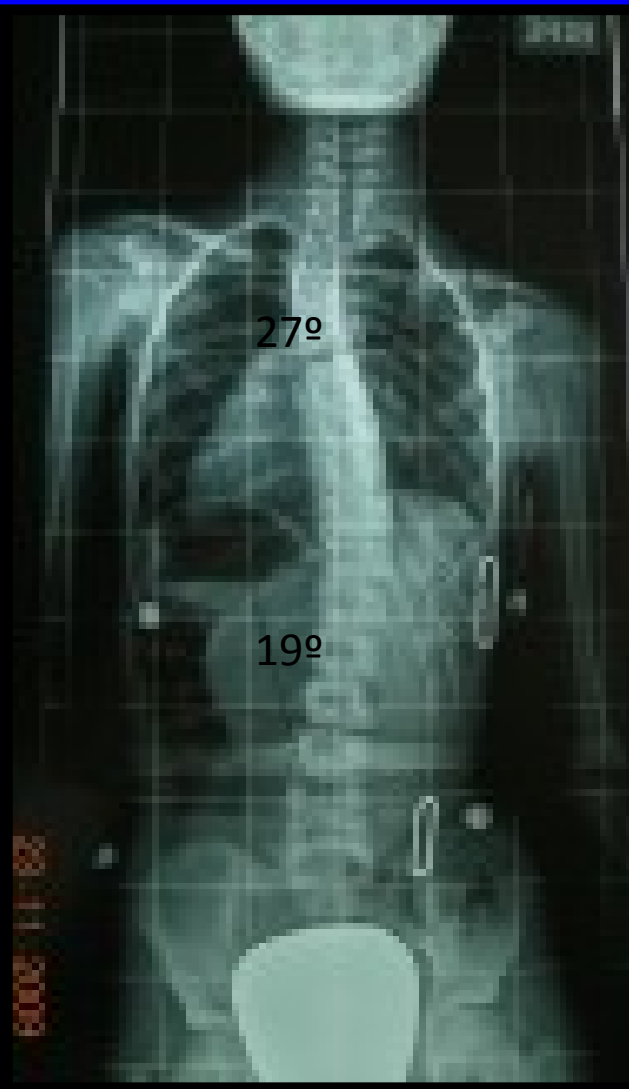
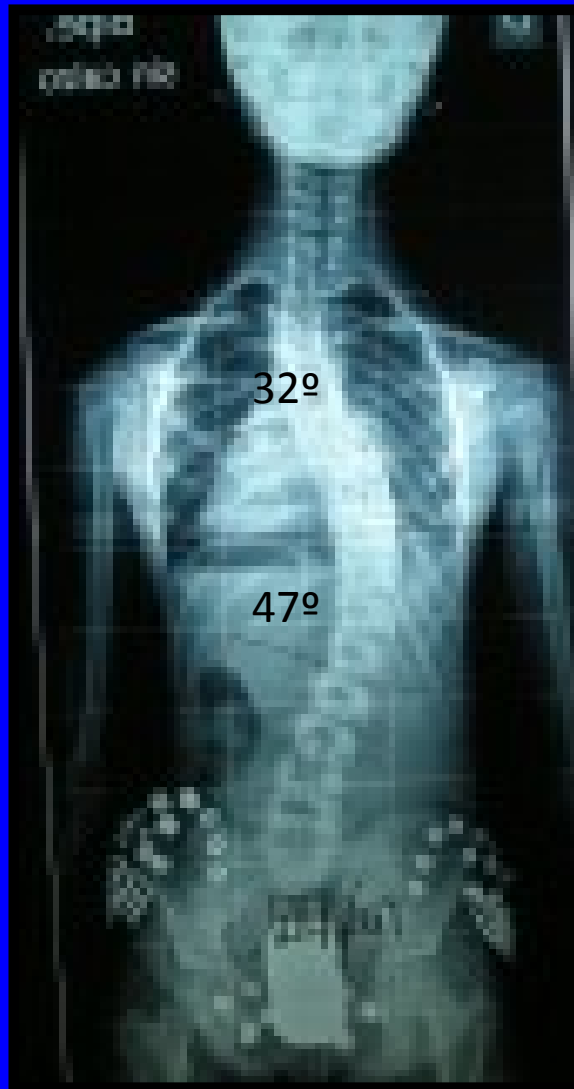Sept. 10



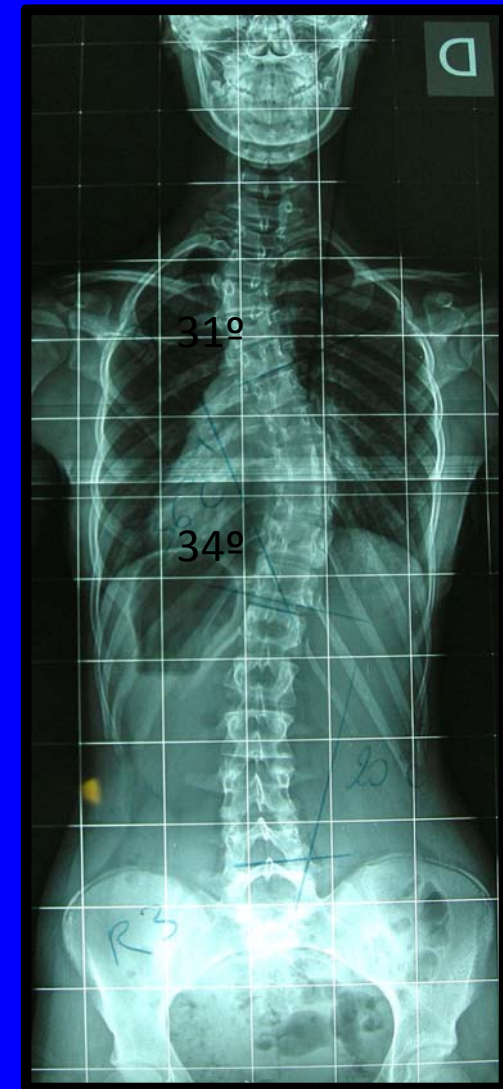At two years of treatment

Sept. 11

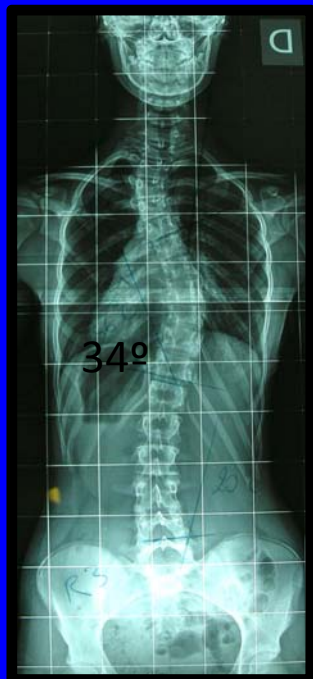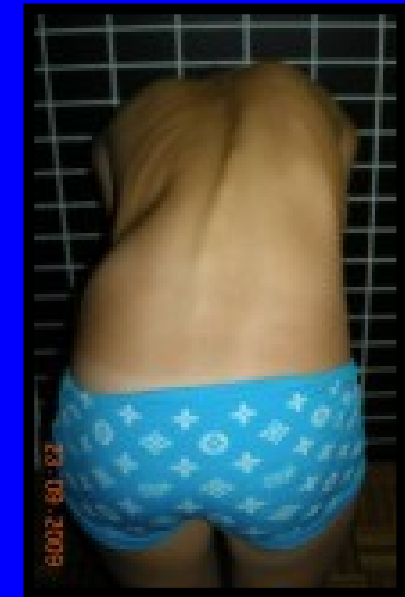

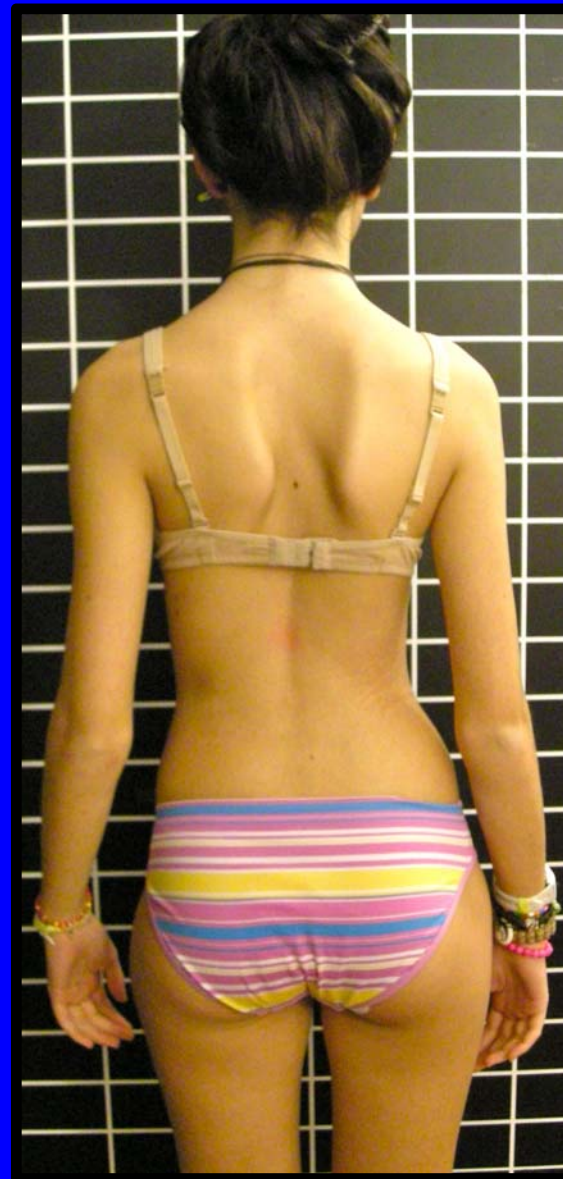
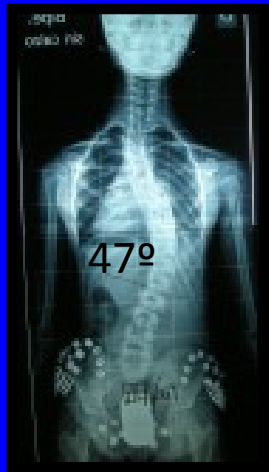


10 y



14 y R3 2 y post-men



14 y
2 post-men
R 3



Thank You



Home sweet home